

Evidence-Based Retreatment of #12 with Perforation Repair and Bioceramic Obturation

CASE PRESENTATION

A 39-year-old male presented with a chief complaint associated with the maxillary left first premolar. The patient had undergone previous root canal therapy followed by post placement and full-coverage crown restoration several years prior at another dental clinic.

Radiographic examination (Fig. 1) demonstrated a previously treated canal with a post in situ and a large periapical radiolucency involving both roots. Persistent apical radiolucency following root canal therapy is most commonly associated with intraradicular infection, missed anatomy, or inadequate coronal seal.

Clinically, the tooth was tender to percussion, palpation, and biting. A buccal sinus tract was present, indicating chronic drainage of periapical infection. No intraoral or extraoral swelling was observed.

Based on clinical and radiographic findings, a diagnosis of previously treated root canal therapy with chronic apical abscess was established. Nonsurgical endodontic retreatment was recommended, as literature supports retreatment as the first-line approach when persistent infection is suspected and the tooth is restorable.

STEP-BY-STEP PROCEDURE

Anesthesia and Isolation

Profound anesthesia was achieved using three carpules of 2% lidocaine with 1:100,000 epinephrine via buccal and palatal infiltration.

Rubber dam isolation was placed to ensure aseptic control, as strict isolation is critical in preventing salivary contamination and bacterial reintroduction during retreatment. Kool-Dam™ (Pulpdent®) liquid rubber dam was applied over the clamp to enhance the seal and reinforce isolation

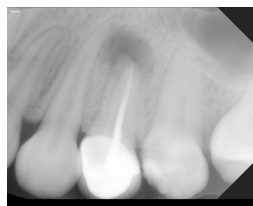


FIG 1
Radiographic examination demonstrated a previously treated canal with post in situ and large periapical radiolucency involving both roots.

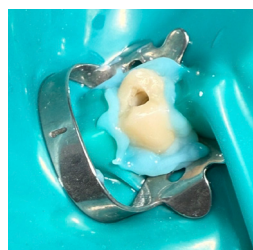

FIG 2
Liquid rubber dam was applied to enhance seal and reinforce isolation.

(Fig. 2). Effective isolation is consistently cited as a determinant of endodontic success.

Access and Post Removal

Access was initiated through the existing porcelain crown using fine diamond burs under copious water irrigation to minimize heat generation and preserve the integrity of the restoration.

A surgical 557 bur was used to refine the access cavity, taking care not to disrupt the coronal aspect of the post. Ultrasonic instrumentation (Cavitron®, Dentsply Sirona) was then utilized to conservatively loosen and remove the post. Ultrasonics have been shown to reduce the risk of root fracture and preserve radicular dentin during post retrieval.

Following post removal, inspection of the chamber revealed a previously untreated palatal canal, identified using a DG-16 explorer. Missed canals are a well-documented cause of persistent apical pathology, particularly in maxillary premolars, which often exhibit complex canal morphology.

A small pulpal floor perforation was also noted after post removal. Perforations compromise prognosis due to communication between the root canal system and the periodontal attachment apparatus. Immediate sealing is critical to prevent epithelial downgrowth and inflammatory breakdown.

Perforation Repair with Root Repair Material

A calcium silicate-based root repair material was placed to seal the perforation defect (Fig. 3) using a single-dose dispensing system (Fig. 4). Calcium silicate materials have demonstrated:

- High biocompatibility
- Alkaline pH with antimicrobial properties
- Bioactivity with hydroxyapatite formation
- Favorable sealing ability in perforation repair




FIG 3 EdgeUtopia™ RRM Root Repair Material (EdgeEndo®)



FIG 4 EdgeUtopia RRM Dispensing Gun (EdgeEndo)

Studies have shown that calcium silicate-based materials promote cementogenesis and periodontal ligament attachment when placed in perforation sites. Their hydrophilic nature allows setting in the presence of moisture, which is particularly advantageous in furcal or pulpal floor perforations. Although moisture control is of utmost importance, especially during Endodontic therapy, we have various instruments to guide us through success, this RRM being one of the fundamentals to establishing a healthy balance of microorganisms in the chamber.

Immediate repair re-established structural integrity prior to canal instrumentation.

Glide Path and Canal Shaping

After removal of gutta-percha from the buccal canal using chloroform, working lengths were established with an electronic apex locator, a method shown to improve working length accuracy compared to radiographs alone.

Apical patency was re-established using #8 and #10 K-files. Re-establishing patency in retreatment cases is essential to disrupt persistent biofilm and enhance irrigant penetration.

A 17.04 rotary glide path file was then taken to working length, followed by shaping with a rotary nickel-titanium sequence (S1, S2, F1).

Instrumentation Parameters:

- File sequence: X7 17.04, S1, S2, F1
- Speed: 350 RPM
- Torque: 3.5 Ncm

Nickel-titanium rotary systems improve shaping efficiency while maintaining canal curvature, reducing procedural errors such as transportation or ledging.

Irrigation Protocol

Throughout instrumentation, irrigation was performed using 5% sodium hypochlorite, the gold standard irrigant due to its tissue dissolution capacity and broad antimicrobial effect.

An adjunct disinfecting solution was used following shaping to enhance smear layer removal and bacterial reduction which is known as the Edge Mix™ (EdgeEndo). The Edge Mix has a dual-irrigant solution mix of EDTA and CHX (chlorohexidine), properties of which enhance the shaping and cleaning process during Endodontic therapy.

Recapitulation with a #10 K-file maintained apical patency and improved irrigant exchange.

Final irrigation consisted of 5% sodium hypochlorite followed by a saline flush prior to drying with sterile paper points.

Effective irrigation is widely recognized as the primary determinant of microbial reduction, as instrumentation alone cannot predictably eliminate biofilm.

Obturation with Bioceramic Sealer

After drying the canals, a premixed calcium silicate-based bioceramic sealer was delivered using an intracanal tip (Fig. 5). The canal space was filled with sealer, and a gutta-percha cone was seated to working length using a single-cone obturation technique. The procedure was repeated for the second canal. Calcium silicate sealers have demonstrated:

- Chemical bonding to dentin
- Biomaterialization at the sealer-dentin interface

- High pH during setting
- Low solubility
- Favorable periapical tissue response

Research indicates that when used with bioceramic sealers, the single-cone technique can achieve comparable sealing ability to warm vertical compaction due to the material's bioactive interface and dimensional stability.

The hydrophilic setting reaction makes these sealers particularly suitable in cases with apical pathology, where residual moisture may be present.

EdgeTemp™ (EdgeEndo) was placed to restore the access cavity. The final radiograph confirmed adequate obturation of both canals and successful completion of nonsurgical retreatment therapy (Fig. 6).

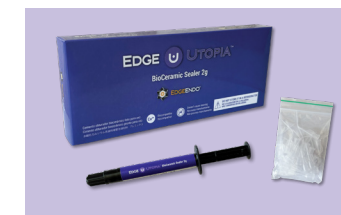

FIG 5
EdgeUtopia Bioceramic Sealer (EdgeEndo)

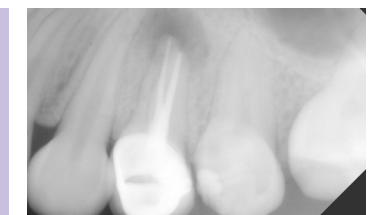


FIG 6
Final radiograph demonstrating successful nonsurgical retreatment.

Conclusion


Root canal therapy demonstrates high long-term success rates when infection is adequately eliminated and a three-dimensional seal is achieved. However, persistent apical pathology may occur due to missed canals, inadequate disinfection, iatrogenic errors, or procedural complications.

This case illustrates several evidence-based principles:

- Retreatment should prioritize microbial elimination.
- Missed anatomy must be reassessed and addressed.
- Perforations require immediate biologically compatible repair.
- Irrigation plays a primary role in bacterial reduction.
- Calcium silicate-based materials support bioactivity and periapical healing.

Even in cases complicated by perforation and post removal, contemporary instrumentation systems and bioceramic materials allow predictable retreatment outcomes while preserving the natural dentition.

With accurate diagnosis, strict isolation, biologic defect repair, effective shaping and disinfection, and bioactive obturation, successful nonsurgical retreatment can be achieved, as demonstrated radiographically in Fig. 6.



DR. STEVEN KALE

is a general dentist with advanced training in endodontics. A graduate of NYU College of Dentistry, and an active associate member of the American Association of Endodontists. He practices in New York City where he is committed to patient care, education, and clinical excellence. He actively shares his work and passion on endodontics on Instagram @dr.kale_endo.

